

Tissue Doppler, strain and strain rate echocardiography in healthy newborns and infants

Elkiran O. (1), Karakurt C. (1), Kocak G. (1), Karadag A. (2)
 Inonu University, Faculty of Medicine, Department of Pediatric Cardiology, Malatya, Turkey (1);
 Inonu University, Faculty of Medicine, Department of Neonatology, Malatya, Turkey (2)

Objective: To evaluate the value of tissue Doppler, strain and strain rate echocardiography in healthy infants. **Materials and Methods:** 149 healthy babies aging between 1 day and 3 months were included in this study. Subjects were separated to four groups: thirty-two healthy preterm infants (36-37 weeks of gestational age, group 1), thirty-two healthy term infants (≥ 38 weeks of gestational age, group 2), forty-seven healthy infants (1 month of postnatal age, group 3) and, thirty-eight healthy infants (3 month of postnatal age, group 4). Standard echocardiographic evaluations, pulsed wave Doppler, tissue Doppler, strain and strain rate study for the left ventricle were applied by same person using a MyLab50 echo machine (Esaote, Florence). **Results:** Mitral E and mitral A velocities determined by pulsed wave Doppler echocardiography were increased from group 1 to group 4. But this increasing was not statistically significant between group 3 and group 4. Mitral A' velocity determined by tissue Doppler echocardiography was increased from group 1 to group 4. This increasing was found significant statistically between group 2 and group 3, group 2 and group 4, group 3 and group 4, group 1 and 3, and group 1 and group 4 ($p=0.001$). Mitral E' velocity determined by tissue Doppler echocardiography was increased from group 2 to group 3 ($p=0.005$), from group 1 to 3 ($p=0.001$) and, from group 1 to 4 ($p=0.001$). The longitudinal and circumferential velocity, strain and strain rate values decreased from base to apex in all subjects ($p<0.001$), (Table, Figure). **Conclusion:** Significant cardiac hemodynamic alterations have been occurred during the newborn and early infancy period.

Table. Values of longitudinal left ventricular systolic strain

		Segment	Group 1	Group 2	Group 3	Group 4
Apical 4 Chambers	Septal	Basal	-13.54±2.67 ^β	-13.89±2.54 ^α	-14.47±1.91 ^ε	-15.72±1.49
		Mid	-10.41±2.48 ^β	-10.58±2.60 ^α	-11.40±2.01	-12.56±1.98
		Apical	-5.65±2.05 ^β	-6.28±2.33 ^α	-6.58±1.71	-8.15±2.11
	Lateral	Basal	-14.34±2.56	-14.69±3.04	-15.21±1.87	-14.89±2.23
		Mid	-10.81±2.34	-11.66±3.03	-11.58±1.63	-11.34±2.24
		Apical	-6.29±1.72	-6.76±2.28	-7.06±1.43	-7.24±1.68

^β=Between Group 1 and Group 4 $p<0.05$, ^α=Between Group 2 and Group 4 $p<0.05$, ^ε=Between Group 3 and Group 4 $p<0.05$

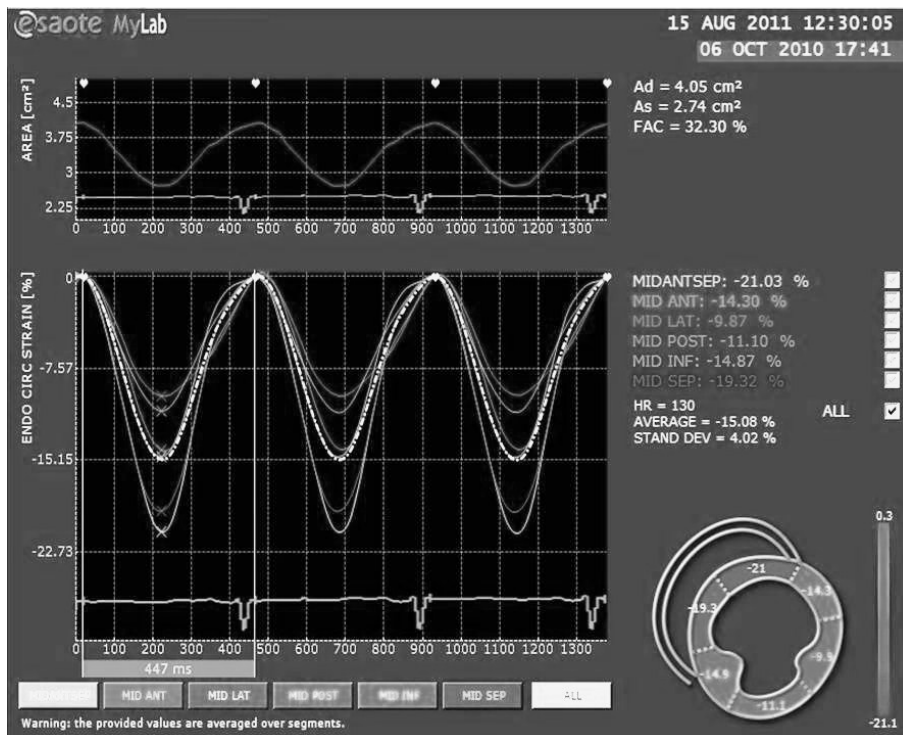


Figure. Circumferential strain analyses of a short axis view