

Left ventricular pump function in Duchenne muscular dystrophy

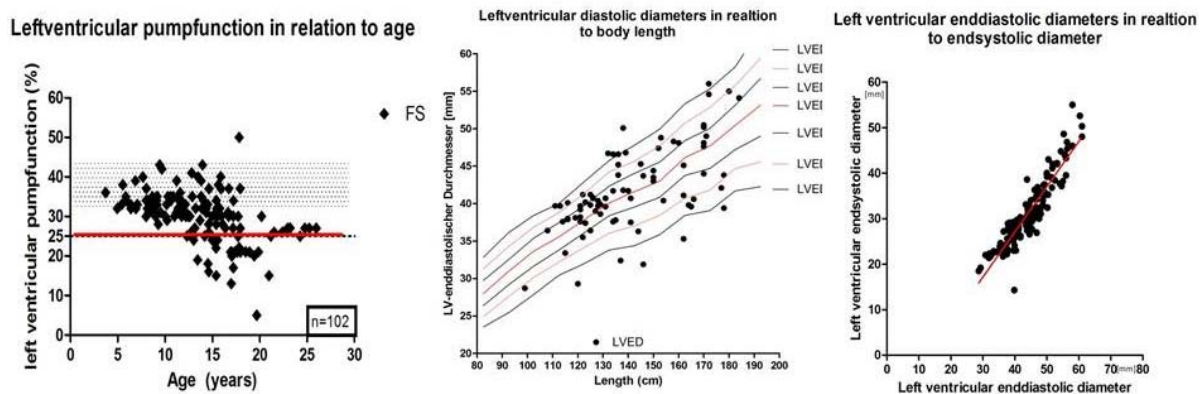
Motz R. (1), Viemann M. (1), Schumacher M. (1), Fiedler K (1), Wagner M. (2), Korenke C. (3)

(1) Departement of pediatric cardiology, Klinikum Oldenburg(2) Social pediatric centre(3) Departement of pediatric neurology, Klinikum OldenburgOldenburg, Germany

Introduction: Patients with muscular dystrophy develop a left ventricular dysfunction during life. Our impression was that left ventricular dysfunction starts during puberty, with an initial increase of the left ventricular diastolic diameter, which was smaller than expected for the body length. Whereas other echo dimension seemed within the normal range. We analyzed our data base to verify our impression.

Method: We had 102 patients with muscular dystrophy assessed echocardiographically. A total of 150 examinations were done with an age range from 3,8 to 21,5 years with a median of 11,2 years (mean 11,5 +/- 3,7 years). We measured the aortic, pulmonary valve diameter in 2 d-echo and left ventricular diameters and function in the classical m-mode. The analysis was done using prizm 6.0.

Results: The left ventricular pump function started to decline after the age of 12 years. In some patients being on beat-blockers and ACE-inhibitors it remained reduced with a fs of about 25%, in others it declined further, in some patients close to end of life situation the medication had to be discontinued due to severe hypotension. Interestingly there was a linear growth of the left ventricular end-diastolic and end-systolic diameter of 1 with a set off of 12mm. The end-diastolic diameter was



normal for body length. The aortic root grew as expected with the body length.

Discussion: To our surprise were the left ventricular diameter within the normal range throughout the observation period. The declining pumpfunction seems to be due to a linear increase of the left ventricular end-systolic diameter; which showed a linear growth with the end-diastolic diameter. The end-diastolic diameter stayed within the normal range, so not comparable to a classic dilating cardiomyopathy were all diameter are out of the normal range.