

Kawasaki disease, Clinical Characteristics and Risk Factors for Coronary Aneurysm in Children Hospitalized in Three Hospitals in Level IV 2000-2012

Culqui K. (1), Carril M. (1), Del Aguila O. (1), Rodriguez J. (1), Avila C. (1), Silva J.(1)
Essalud (Seguridad Social del Perú) (1); Lima - Peru

INTRODUCTION

Kawasaki disease is a vasculitis of unknown etiology, affecting blood vessels of small and medium caliber, the main complication is the formation of coronary artery aneurysms. It is the leading cause of acquired heart disease in children in developed countries.

In 2011 an outbreak was observed in our environment, so it is important to understand clinical manifestations, complications and seek risk factors associated with the development of coronary artery abnormalities

OBJECTIVES

To determine the clinical and laboratory features that relate to the development of coronary artery abnormalities in patients hospitalized with the diagnosis of Kawasaki disease in three hospitals in level IV between 2000-2012.

RESULTS I

70 cases were observed in twelve years, being more common in males. The largest number of cases in children under 2 years.

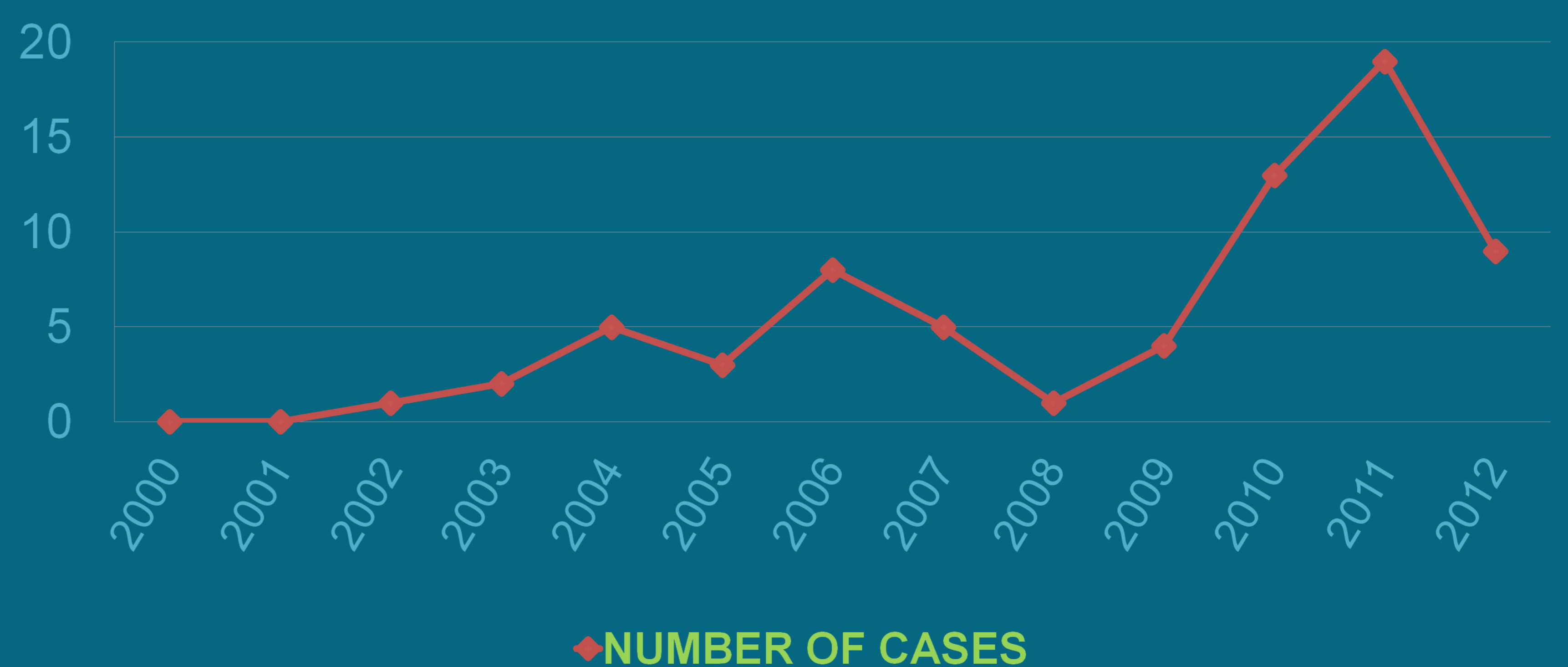The main clinical manifestations fever, changes in the oral mucosa, bilateral conjunctival hyperemia, exanthem, changes in the extremities and cervical lymphadenopathy less frequent.

In laboratory data include C-reactive protein, leukocytosis, thrombocytosis, anemia and increased transaminases.

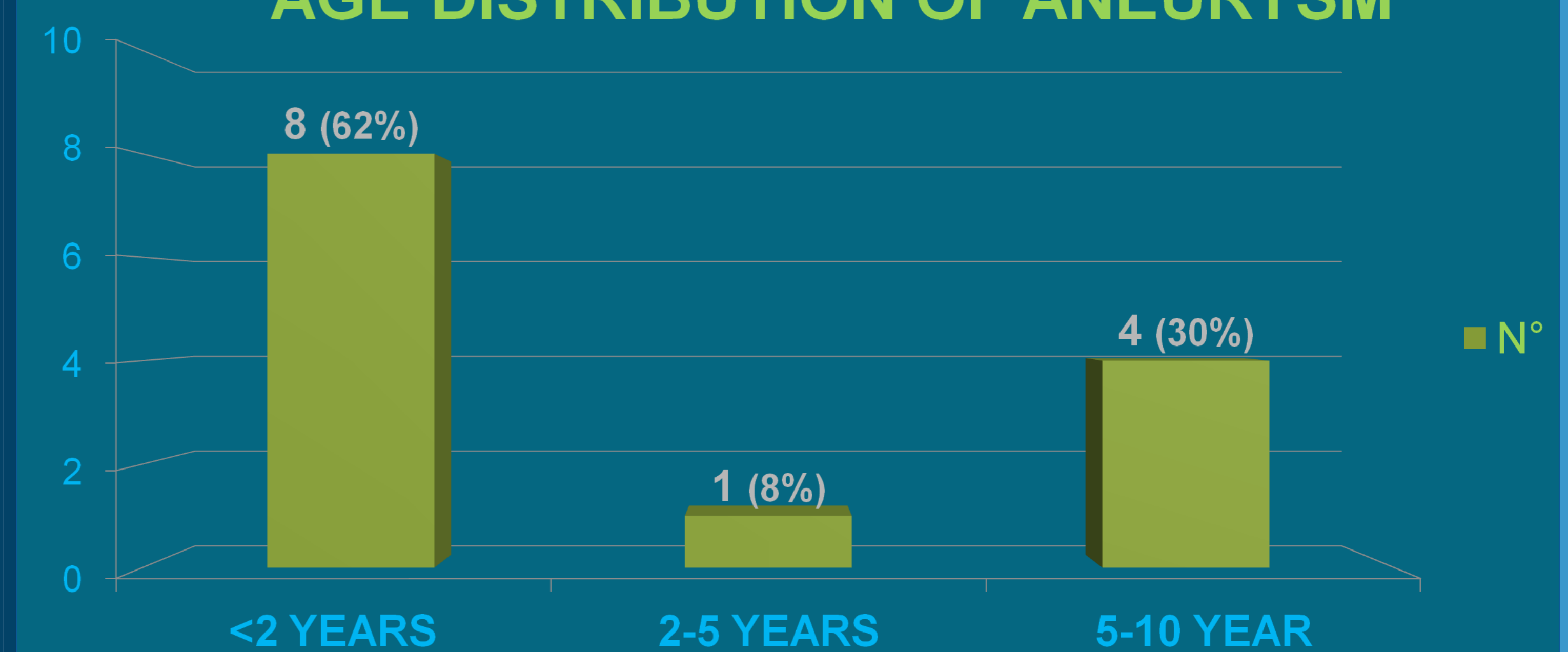
Cardiac complications occurred in 38%, being the most common coronary aneurysms and second coronary dilation and thirdly spill pericardial. Male sex (OR = 2.5), exanthem (OR = 1.3) and CRP > 10mg/dl (OR = 6.4) were identified as risk factors for coronary aneurysms.

RESULTS II

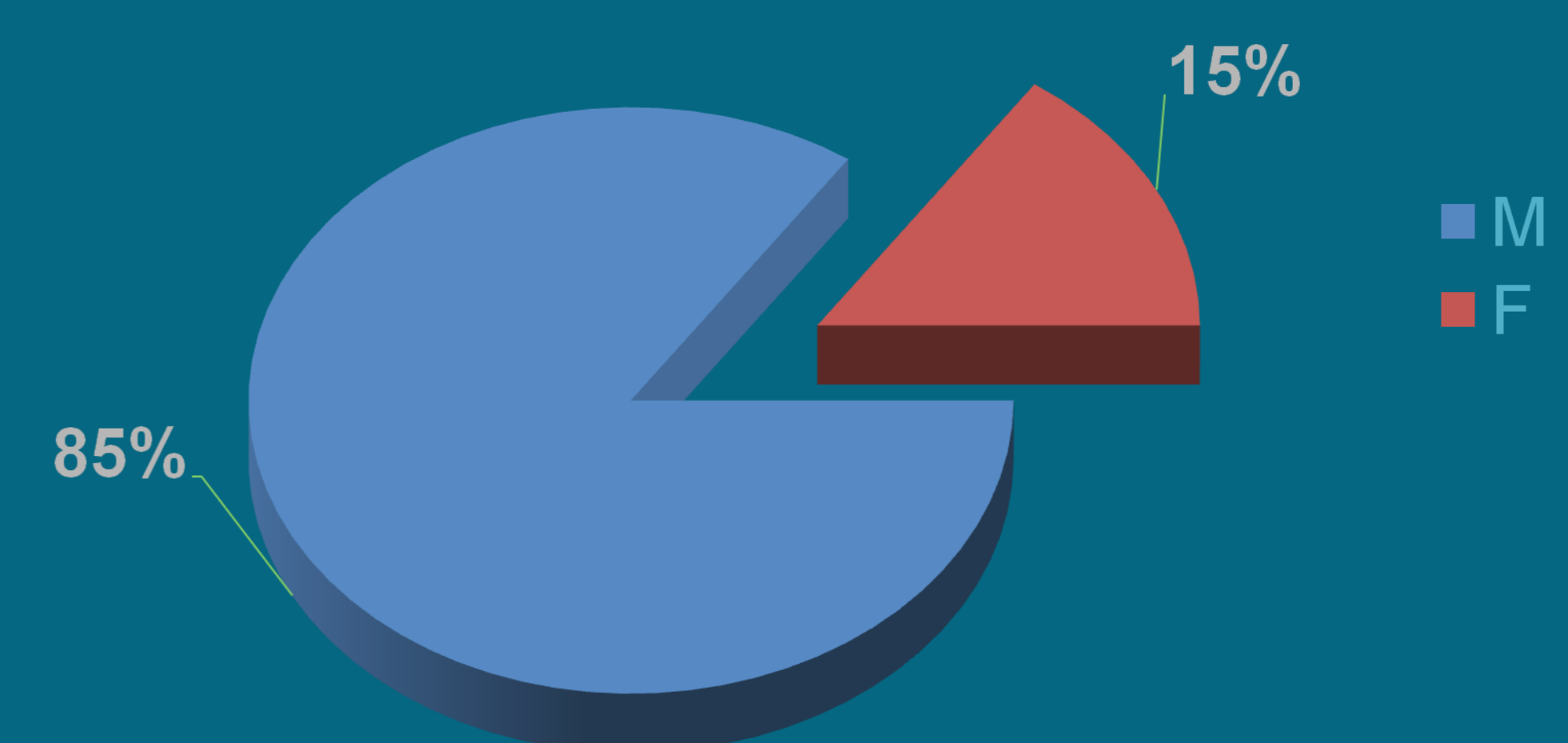
KD: DISTRIBUTION OF CASES PER YEAR



AGE DISTRIBUTION OF ANEURYSM



ANEURYSM DISTRIBUTION BY SEX



CONCLUSIONS

The typical Kawasaki disease is the most common. Kawasaki disease is on the rise in recent years, early diagnosis and early treatment prevents complications.